Heliyon 10 (2024) e35205

Contents lists available at ScienceDirect

Heliyon

journal homepage: www.cell.com/heliyon

Research article

Efficacy and safety of a new torque-controlled angiographic catheter in cerebral angiography: A multicenter, randomized, open-label trial

Seung Min Shin [a], Ji Young Lee [a], Heo Nam Hun [b], Se Woong Choo [c], Yong Pyo Jeon [c], Jaewoo Chung [d], Jung Ho Ko [d], Hae-Won Koo [e], Dong Seoung Shin [f], Man Ryul Lee [g], Jae Sang Oh [a,h,*]

[a] Department of Neurosurgery, Soonchunhyang University Cheonan Hospital, College of Medicine, Soonchunhyang University, Cheonan, Republic of Korea
[b] Clinical Trial Center, Soonchunhyang University Cheonan Hospital, Cheonan, Republic of Korea
[c] Division of STENT, GENOSS, Suwon, Republic of Korea
[d] Department of Neurosurgery, Dankook University Hospital, College of Medicine, Dankook University, Cheonan, Republic of Korea
[e] Department of Neurosurgery, Ilsan Paik Hospital, College of Medicine, Inje University, Goyang, Republic of Korea
[f] Department of Neurosurgery, Soonchunhyang University Bucheon Hospital, College of Medicine, Soonchunhyang University, Bucheon, Republic of Korea
[g] Soonchunhyang, Institute of Medi-Bio Science (SIMS), Soonchunhyang University, Cheonan, Republic of Korea
[h] Department of Neurosurgery, Uijeonbu St. Mary's Hospital, College of Medicine, The Catholic University of Korea, Uijeonbu, Republic of Korea

ARTICLE INFO

Keywords:
Cerebral angiography
Catheters
Femoral artery
Torque-controlled
Carotid artery
Rotation force

ABSTRACT

Objective: We aimed to examine the effectiveness and safety of a novel torque-controlled catheter for cerebral angiography.

Methods: A total of 417 patients who underwent routine transfemoral cerebral angiography were enrolled in a randomized controlled study to compare the new torque-controlled and control group catheters. Device success was assessed on parameters such as the assessment of the common carotid artery, device rotation force, and success rate with the crossover group after the failed procedure. Four neurointerventionalists investigated the degree of satisfaction of using the new device. Superiority and non-inferiority tests of satisfaction scores were estimated for the new torque-controlled and the control group catheters.

Results: The new torque-controlled catheter showed improved performance in terms of technical device success (92.79 vs. 98.09 %, $P = 0.010$), crossover after technical device failure (0 vs. 86.67 %, $P = 0.004$), and common carotid artery access (92.79 vs. 98.56 %, $P = 0.004$). The flexibility and rotational force of the new torque-controlled catheter were higher than those of the control group catheters (75.48 vs. 100 %, $P < 0.001$). No marked adverse cerebrovascular accidents or vessel damage occurred in either group during the procedure. The differences between the two groups in terms of the device rotational force and operator satisfaction were 1.836 (1.765–1.907) and 2.092 (2.000–2.183), respectively. The new torque-controlled catheter showed superior device rotational force satisfaction, operator satisfaction, and manufacturer satisfaction, with statistical significance.

* Corresponding author. Department of Neurosurgery Uijeonbu St. Mary's Hospital College of Medicine The Catholic University of Korea, 271 Cheonbo-ro, Uijeonbu 11765, 31151, Republic of Korea.

E-mail address: metatron1324@hotmail.com (J.S. Oh).

https://doi.org/10.1016/j.heliyon.2024.e35205
Received 27 November 2023; Received in revised form 23 July 2024; Accepted 24 July 2024
Available online 26 July 2024
2405-8440/© 2024 The Authors. Published by Elsevier Ltd. This is an open access article under the CC BY-NC-ND license (http://creativecommons.org/licenses/by-nc-nd/4.0/).

Conclusion: The new torque-controlled catheter was effective, safe, and convenient compared to the control group catheters for diagnostic cerebrovascular angiography.

1. Introduction

Although it is considered an invasive method, cerebrovascular angiography is one of the most accurate diagnostic tools for intracranial vessels [1,2]. A cerebral angiographic catheter should be a long tube to easily access the distal to the internal carotid artery or vertebral artery, and is used to observe blood vessels with contrast injection. In previous studies [3–8], the complication rates in cerebral angiography ranged from 1 % to 12 %, and neurological complications occurred in 0–5 % of patients. Vessel complications, such as arterial dissection or plaque dislodgement, occur when the catheter tip touches the intimal layer of the vessel or forcefully attempts to enter the curved blood vessel for a long time. Therefore, the stability and flexibility of the cerebral angiographic catheter are particularly critical for achieving a high success rate and ensuring a low complication rate as it must pass through an extremely small multi-branched path with severe curvature. Conventional diagnostic catheters typically have an outer diameter of 5 French (Fr) and an inner diameter of approximately 0.038 [9]. A conventional 0.035-inch guidewire is installed, and simultaneous contrast injection is impossible. Therefore, the wire is inserted and removed repeatedly. Repeated insertions and removals lead to changes in the shape of the tip, which can come in contact with the blood vessel wall and cause dissection, thrombus, or air embolism during high-pressure contrast injections, such as that during three-dimensional rotational angiography. In the newly designed cerebral angiographic catheter, the entire guidewire need not be removed. Therefore, cerebral angiography can be performed using a continuous flushing system with a hemostatic valve and a pressured saline bag. Furthermore, these differentiated systems are safer and more stably positioned during contrast injection, even in highly tortuous carotid and vertebral arteries. The new torque-controlled catheter is designed to be more flexible and have a higher torsional stiffness than those of previously used catheters through a multi-segmented design.

This study aimed to examine the effectiveness and safety of the new torque-controlled angiography catheter in cerebral angiography by comparing it with the existing control group catheters.

2. Materials and Methods

2.1. New torque-controlled angiographic catheter

The main specifications of the catheter include the polymer material and braided specifications. The polymer material and structure comprise of three multi-segment components (Fig. 1). Three Pebax materials were combined with the braid wire made of stainless steel; the picks per inch (PPI) specifications were selected to compensate for the loss of flexibility of the chosen material and increase the torque transmission power. Shaft flexibility and durability were thus reinforced in the catheter for insertion in curved blood vessels.

The braided wire specification of the catheter is directly related to the rotational torque force and flexibility performance [10,11]. This product comprises 16 wires arranged in a 2 × 2 pattern and reinforces the durability and flexibility of the catheter in the radial direction. The crucial specification of the braided structure is PPI, which is the number of patterns per inch. In this case, because

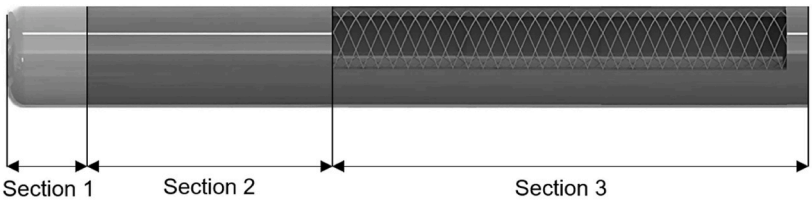

Section #	Part Name	Material	Hardness
1	End tip	Pebax 3533	25D
2	Non-braid shaft	Pebax 5533	50D
3	Main shaft	Pebax 7033	61D

Fig. 1. Multi-joint shaft structure of New torque-controlled catheter. (A) Schematic diagram of three multi-segment components of torque-controled catheter, (B) Material and hardness of three multi-segment torque-controled catheter.

flexibility and torque transmission power have opposite relationships, optimized specifications are required. The most optimized specifications, that is, 55 PPI and a braid angle of 91.5°/88.5°, were selected (Fig. 2).

The optimized polymer material and braided wire specifications required matching to the outer/inner diameter based on the diameter of the vascular lesion in the patient to attain flexibility to enter the aorta and carotid artery and achieve excellent rotational performance within the lesion. Furthermore, an increased outer/inner diameter led to appropriate injection/recovery performance of the contrast agent.

2.2. Study design

This was a prospective, multicenter, randomized, open-label, double-arm trial to investigate the efficacy and safety of a new torque-controlled catheter. To randomly allocate subjects to each group, statisticians independent of this clinical study used SAS Version 9.4 (SAS Institute Inc., Cary, NC, USA) to apply the block randomized allocation method and prepare a random allocation table. The assignment code of each study subject was available to the researcher before the study was initiated, and the researcher opened the assignment codes in the order of the registration of the study subjects to check the random assignment group and apply either the new torque-controlled or the control group catheter. Randomization was performed using a web service (http://hcs.icrf.co.kr/crflogin.bes). The study was conducted in four universities. Each of the four hospitals had an independent operator, all of whom are experts in cerebrovascular diseases, that is, a physician certified by the Korean Neuroendovascular Society who performs more than 300 cerebrovascular procedures in a year. Each physician received standardized angiography training before the start of the clinical trial. Eligible subjects were assigned to one of the two groups in equal proportion. Randomization was performed under local anesthesia using a sealed envelope containing a computer-generated random number generated by the investigator. Each patient received the allocated index procedure based on the assigned group. The study procedure in intervention group A was performed using the new torque-controlled angiographic catheter (Genoss initiator; GENOSS Co. Ltd., Suwon, Korea). The same procedure was performed in control group B with existing catheters used for cerebral angiographies, e.g., the Cook (Beacon; CooK Medical, Bloomington, IN, USA) and Terumo (Radifocus; Terumo Medical, Tokyo, Japan) catheter. This study was performed following the ethical guidelines of the 1975 Declaration of Helsinki. Written informed consent was obtained from each participant after providing a complete explanation. The institutional review boards of all the participating hospitals approved this study. This trial has been registered on the appropriate trial registry platform.

2.3. Study subjects

The inclusion criteria were as follows: 1. patients undergoing transfemoral cerebrovascular angiography; 2. patients aged between 18 and 80 years; and 3. patients who provided written informed consent to participate in the study.

The exclusion criteria was as follows: 1. inability to evaluate complications due to severe neurological disorders with a score ≥3 on the modified Rankin scale; 2. patients who previously underwent vascular or cardiac open surgery or interventional stenting; 3. patients with congenital diseases, such as sickle cell disease, Marfan syndrome, polycystic kidney disease, and Ehlers-Danlos syndrome, which are well-known high-risk factors for vascular damage during cerebrovascular angiography; and 4. patients for whom it was

		Initiator	Control catheter
Shaft Structure		3-segment / Straight	2-segment / Distal Tapered
Outside Diameter/ Inside Diameter (mm)		1.70/1.20 (T: 0.25)	1.65 / 1.05 (T: 0.30)
Braid Wire	Wire (mm)	Dual round 16wires OD 0.04 x 2ea	Single round 16wires OD 0.06
	Pattern	2x2	2x2
	Angle	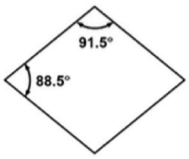	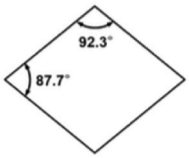
	PPI	55	50

Fig. 2. Catheter specification of New torque-controlled catheter.

difficult to access the femoral artery owing to obesity, severe steno-occlusive lesions, aortic aneurysms, or dissection.

2.4. Angiographic procedure

Four neurointerventionalists performed all procedures. Prior informed consent was obtained from all patients. The femoral artery sheath was punctured, and cerebral angiography was performed using the new torque-controlled angiographic catheter (Genoss initiator; GENOSS Co. Ltd.), a Cook catheter (Beacon; Cook Medical), and a Terumo catheter (Radifocus; Terumo Medical) (Fig. 3a).

A continuous irrigation system was connected to a three-way hub, and a cerebral angiogram was obtained while a 035 Terumo wire was mounted into the new torque-controlled catheter. A left internal carotid angiogram was obtained (Fig. 3b). Live images using the new torque-controlled and control group catheters (Fig. 3c and d) were captured to show the differences between the clarity and radiopacity of the catheters during cerebral angiography.

The catheter tip was controlled to select the orifice of the target artery and then advanced distally. Routine cerebral angiography was performed for the right brachiocephalic, right common carotid, right internal carotid, left common carotid, left subclavian, and dominant vertebral arteries, followed by three-dimensional rotation angiography for specific lesions. When various types of catheters in both groups failed to access the target artery, they were retried and exchanged with the catheter of the opposite group. For example, if the Cook or Terumo catheter failed to access the right common carotid artery, the new torque-controlled catheter was attempted in the next step. Access site hemostasis was achieved via manual compression.

Each artery was selected using a roadmap prepared from its proximal entrance, and the guidewire was advanced into the target vessel and catheter follows along the guidwire. The catheter approached the aortic arch within 4 cm of the bifurcation of the common carotid artery. In cases of severe stenosis of the cervical arteries, an angiogram was obtained in the proximal portions, such as the common carotid or subclavian arteries. Pre-determined injection flow rates and volumes were used depending on the vessel size and

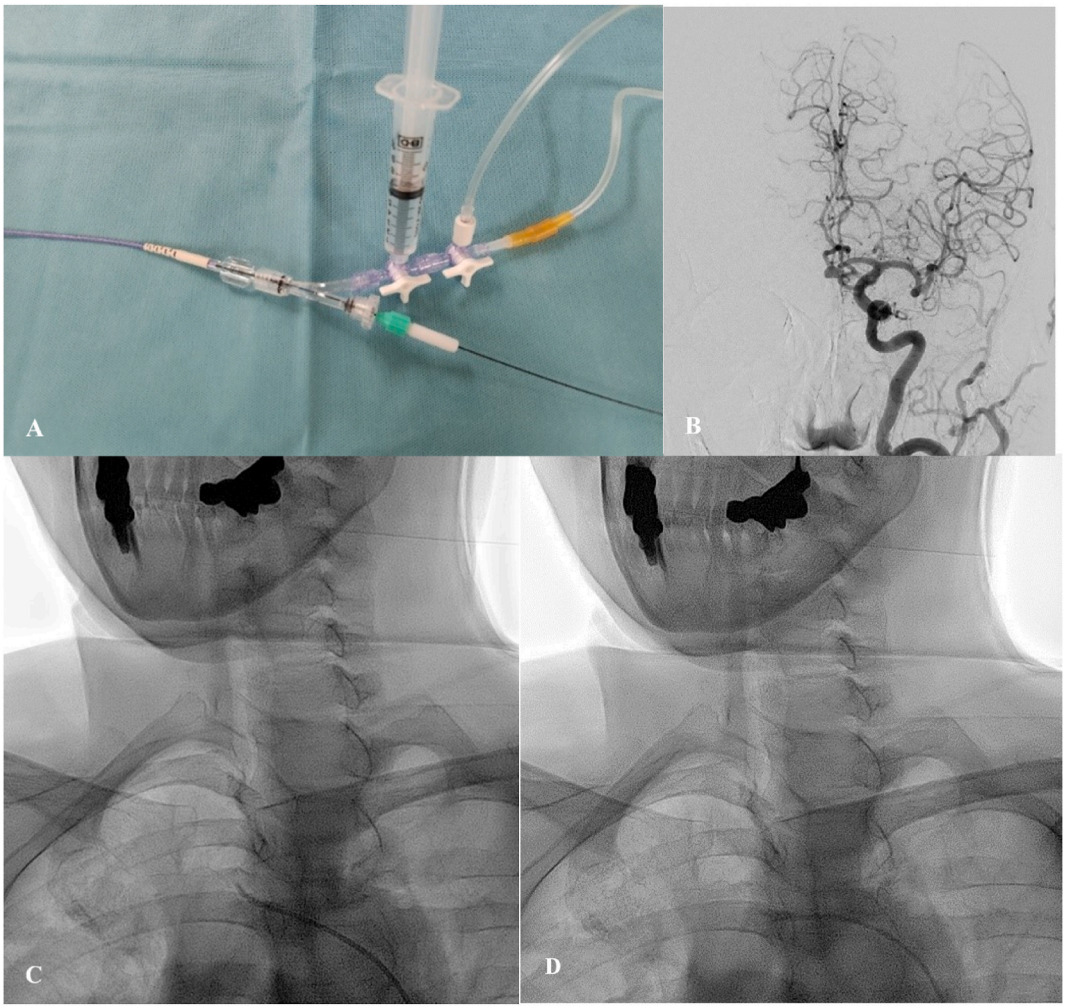

Fig. 3. (A) Initial setting of new torque-controlled catheter, (B) Angiography performed by new torque-controlled catheter, (C) new torque-controlled catheter on fluorography (D) control group catheter on fluorography.

anatomic variation, that is, 4, 2, and 3 mL/s and 6, 3, and 5 mL for the internal carotid, external carotid, and vertebral arteries, respectively. After cerebral angiography, all patients were observed for 6 h during bed rest.

2.5. Efficacy assessment

The primary efficacy endpoint was clinical procedural success. Clinically, procedural success is defined as successful discharge from the hospital after angiography without death, vascular damage, or cardiovascular disease. The secondary efficacy endpoint was technical device success. Successful catheterization and acquisition of three angiograms on both the carotid and vertebral arteries were defined as technical device success, for example, a case in which the medical device reaches the target lesion and obtains an accurate image after successful placement and injection of the contrast agent. If a technical failure occurred, cerebral angiography was performed by crossing over to the alternative catheter.

The degree of flexibility and rotational force of the catheter was divided into good, decreased 1:1 rotation function at tortuous vessels, and whip occurrence at tortuous vessels. A whip is defined as a high-frequency oscillation resulting from the rapid movement of the catheter caused by blood flow [12].

Additionally, a satisfaction survey was conducted to assess the device rotational force satisfaction, operator satisfaction, and manufacturer satisfaction on a 1–5 scale as follows: very dissatisfied = grade 1; dissatisfied = grade 2; ordinary = grade 3; satisfied = grade 4; very satisfied = grade 5.

The satisfaction grade for the flexibility and rotational force of the device is defined as the accuracy of the 1:1 torque rotation. This measurement assesses how closely the rotation angle of the catheter displayed on the screen matches the movement of the hand.

2.6. Safety assessment

The primary safety endpoint was major adverse cerebrovascular events. Major adverse cerebrovascular events were defined as the occurrence and death from cerebrovascular disease caused by a catheter during the procedure. The secondary safety endpoint was vessel damage during this procedure. Intraluminal thrombi, vascular wall damage or dissection, and perforation on angiography were also included.

2.7. Statistical analyses

In this study, the non-inferiority of rotational force satisfaction, operator satisfaction, and manufacturer satisfaction of the new torque-controlled catheter was compared to those of the control group catheters using Blackwelder's method [13].

The primary study hypothesis was that the satisfaction score of the new torque-controlled catheter would be non-inferior to that of the control group catheters.

The assumptions were a one-sided α of 0.025 and a clinically relevant non-inferiority margin of −1. Mathematically, the null hypothesis (H_0) and alternative hypotheses (H_A) can be stated as follows:

$H_{0(\text{non-inferiority})}$: $S_{control} - S_N \geq 1$ ($S_N - S_{control} \leq -1$)

$H_{A\ (\text{non-inferiority})}$: $S_{control} - S_N < 1$ ($S_N - S_{control} > -1$)

where S_N and $S_{control}$ are the mean satisfaction scores noted after the use of the new torque-controlled catheter (S_N) and the control group catheter ($S_{control}$), respectively.

The hypothesis test consisted of the construction of a one-sided 97.5 % confidence interval around the difference in satisfaction score ($S_N - S_{control}$). If the lower bound of the interval was greater than −1, the null hypothesis was rejected, and non-inferiority was established. If non-inferiority of the new torque-controlled catheter was shown, it was planned to test superiority with a one-sided Wald test with the following rules [14]:

$H_{0(\text{superiority})}$: $S_N \leq S_{control}$

$H_{A\ (\text{superiority})}$: $S_N > S_{control}$

Continuous variables were expressed as the mean ± standard deviation or median with interquartile ranges. Categorical variables were expressed as frequencies with percentages. The baseline characteristics and outcomes between the new torque-controlled catheter and the control group catheters were compared using the *chi*-square test. Analyses of device rotational force satisfaction, operator satisfaction, and manufacturer satisfaction were performed using the Student's *t*-test.

All *P*-values were two-sided, and values < 0.05 were considered statistically significant. Statistical analyses were performed using SPSS version 26 (IBM Corp., Armonk, NY, USA).

3. Results

3.1. Baseline characteristics of the patients

From June 2020 to December 2021, 417 transfemoral cerebral angiographies were performed using 209 new torque-controlled

catheters and 208 control group catheters.

The baseline patient characteristics are presented in Table 1. The mean age of the new torque-controlled catheter group was greater than that of the control group (60.17 vs. 59.46 years, $P = 0.609$). The sex ratio between the two groups was not statistically significant ($P = 0.461$).

The distribution of the aortic arch type was as follows: type 1, 120 (57.4 %); type 2, 68 (32.5 %); and type 3, 21 (5.0 %). The proportion of the aortic arch type showed no significant difference between the two groups ($P = 0.813$).

The diagnoses included intracranial aneurysm (48.2 %), intracranial stenosis (17.7 %), extra-cranial stenosis (12.0 %), other diseases not including ischemic or hemorrhagic disease (vessel dissection, arteriovenous malformation, brain tumor, venous abnormality, arteriovenous fistula, carotid-cavernous fistula, and anterior fibromuscular dysplasia) (8.2 %), intracerebral hemorrhage/intraventricular hemorrhage (6.0 %), moyamoya disease (3.8 %), cerebral infarction (2.6 %), other hemorrhagic diseases (non-aneurysmal subarachnoid hemorrhage and chronic subdural hematoma) (0.7 %), and other ischemic diseases (sinus thrombus and vasospasm) (0.7 %).

3.2. Efficacy and safety outcomes

The efficacy and safety outcomes are listed in Table 2. Femoral artery puncture was successful in both groups. Clinically, device success was observed in all cases in both groups. Technically, the device success rate was significantly higher in the new torque-controlled catheter group (92.79 vs. 98.09 %, $P = 0.010$) and device failure was observed in 19 patients.

The new torque-controlled catheter was successful at crossover after technical device failure, with statistical significance (0 vs. 86.67 %, $P = 0.004$).

Fifteen patients in the control group did not undergo transfemoral cerebral angiography for aortic type 2 or 3 with tortuous vessels. In most cases, the catheter failed to select the common carotid artery. However, 13 of the 15 cases were successfully treated after changing to the new torque-controlled catheter. Three of the four cases in the new torque-controlled catheter group failed in aortic type 3, the catheter failed to select the common carotid artery, and there was no success after changing to another catheter in the control group.

Aortic arch access was more successful in the new torque-controlled catheter group but without statistical significance (99.04 vs. 100 %, $P = 0.248$). Common carotid artery access was more successful in the new torque-controlled catheter group compared to the control group with statistical significance (92.79 vs. 98.56 %, $P = 0.004$).

The satisfaction grade for the flexibility and rotational force of the device was significantly higher for the new torque-controlled catheter (75.48 vs. 100 %, $P < 0.001$) than for the control catheters. The rate of decrease in 1:1 rotation function or whip occurrence in tortuous vessels was significantly higher in the control catheter group (17.31 vs. 0 %, 7.21 vs. 0 %, $P < 0.001$). Whip phenomena refer to the sudden jerking or abrupt directional changes of the catheter during 1:1 torque rotation, typically occurring when the 1:1 torque-control capability is insufficient. The new torque-controlled catheter has demonstrated superior 1:1 torque-control capabilities, which is reflected in the satisfaction grade for the flexibility and rotational force of the device. No major adverse cerebrovascular events or vessel damage occurred during the procedure in either group.

Table 1
Baseline characteristics of the patients.

	Total (n = 417)	Control (n = 208)	New torque-controlled catheter (n = 209)	*P*-value
Age, mean ± SD	59.82 ± 14.15	59.46 ± 14.18	60.17 ± 14.13	0.609
Sex				0.461
Male	198 (47.48)	95 (45.67)	103 (49.28)	
Female	219 (52.52)	113 (54.33)	106 (50.72)	
Aortic arch type				0.813
1	237 (56.8)	117 (56.3)	120 (57.4)	
2	134 (32.1)	66 (31.7)	68 (32.5)	
3	46 (11.0)	25 (6.0)	21 (5.0)	
Diagnosis				
Intracranial aneurysm	201 (48.2)	97 (46.6)	104 (49.7)	
Intra-cranial stenosis	74 (17.7)	34 (16.3)	40 (19.1)	
Extra-cranial stenosis	50 (12.0)	27(13.0)	23 (11.0)	
Other disease not including	34 (8.2)	20 (9.6)	14 (6.7)	
Ischemic, hemorrhagic disease				
Intracerebral hemorrhage/intraventricular hemorrhage	25 (6.0)	13 (6.3)	12 (5.7)	
Moyamoya disease	16 (3.8)	7 (3.4)	9 (4.3)	
Cerebral infarction	11 (2.6)	5 (2.4)	6 (2.9)	
Other hemorrhagic disease	3 (0.7)	2 (1.0)	1 (0.5)	
Other ischemic disease	3 (0.7)	3 (1.5)	0 (0.0)	

Data presented as mean ± standard deviation or number (%).
Continuous variables were compared using Student's *t*-test.
Categorical variables were compared using the *chi*-squared test.

Table 2
Catheter efficacy and safety assessment.

	Total (n = 417)	Control (n = 208)	New torque-controlled catheter (n = 209)	*P*-value
Clinically device success				
Success	417	208 (100)	209 (100)	
Fail	0 (0)	0 (0)	0 (0)	
Technically device success				0.010*
Success	398 (95.44)	193 (92.79)	205 (98.09)	
Fail	19 (4.56)	15 (7.21)	4 (1.91)	
Cross over after technical device failure				0.004**
Success	13 (68.42)	0 (0)	13 (86.67)	
Fail	6 (31.58)	4 (100)	2 (13.33)	
Femoral puncture				
Success	417 (100)	208 (49.9)	209 (50.1)	
Fail	0 (0)	0 (0)	0 (0)	
Aortic arch access				0.248
Success	415 (99.52)	206 (99.04)	209 (100.00)	
Fail	2 (0.48)	2 (0.96)	0 (0)	
Common carotid artery access				0.004**
Success	399 (95.68)	193 (92.79)	206 (98.56)	
Fail	18 (4.32)	15 (7.21)	3 (1.44)	
Flexibility and rotational force of device				<0.001***
Good	366 (87.77)	157 (75.48)	209 (100.00)	
Decrease 1:1 rotation function at tortuous vessels	36 (8.63)	36 (17.31)	0 (0)	
Whip occurrence at tortuous vessels	15 (3.60)	15 (7.21)	0 (0)	
Major adverse cerebrovascular event				
Occurred	0 (0)	0 (0)	0 (0)	
Not occurred	417 (100)	208 (100)	209 (100)	
Vessel damage during the procedure				
Occurred	0 (0)	0 (0)	0 (0)	
Not occurred	417 (100)	208 (100)	209 (100)	

Data presented as number (%).
Categorical variables were compared using *chi*-squared or Fisher's exact test.
*$P < 0.05$; **$P < 0.01$; ***$P < 0.001$.

3.3. Device satisfaction

The satisfaction survey results for each group are presented in Table 3. The mean device rotational force satisfaction score was 4.900 ± 0.398 for the new torque-controlled catheter group and 3.064 ± 0.245 for the control group, with a significant difference of 1.836 (1.765–1.907; $P < 0.001$). The mean operator satisfaction was 4.947 ± 0.244 for the new torque-controlled catheter group and 2.856 ± 0.628 for the control group, with a significant difference of 2.092 (2.000–2.183; $P < 0.001$). The mean manufacturer satisfaction was 4.947 ± 0.244 for the new torque-controlled catheter group and 2.875 ± 0.617 for the control group, with a significant difference of 2.072 (1.982–2.163; $P < 0.001$). Therefore, the new torque-controlled catheter was superior in terms of device rotational force, and operator and manufacturer satisfaction (Fig. 4).

3.4. Mechanical thrombectomy using the new torque-controlled catheter

A 58-year-old female patient who visited the hospital with a National Institute of Health Stroke Scale score of 1 was enrolled. Symptoms occurred 3 h before the visit. Brain 3-dimensional computed tomographic angiography (Fig. 5a) revealed distal basal artery occlusion, and simultaneous cerebral angiography and mechanical thrombectomy were conducted [15]. Cerebral angiography was performed using the 5F new torque-controlled catheter. After right and left vertebral artery angiography (Fig. 5b and c), the new torque-controlled catheter was used as a guiding catheter, and a rebar microcatheter (ev3, Irvine, CA, USA) was inserted immediately with a continuous irrigation system (Fig. 3a). The microcatheter was advanced into the left posterior cerebral artery traversing the thrombus, and a Solitaire stent (ev3 Inc., Plymouth, MN, USA) was deployed. The thrombus was retrieved after waiting for 3 min. The final angiogram (Fig. 5d) showed thrombolysis in cerebral infarction of grade 3 after successful recanalization with one-time retrieval. After mechanical thrombectomy, the patient's mental status recovered to a modified Rankin Scale score of 0.

4. Discussion

Compared to the control group catheters, the new torque-controlled catheter is characterized by better accessibility to tortuous cerebrovascular arteries. Three different structures on each of the three multi-segmented shafts resulted in better flexibility and durability of the curved blood vessels. The optimized polymer material and braided wire specifications resulted in wider inner diameters to the maximum dimensions, flexibility to enter the aorta and carotid arteries, and excellent rotational performance of the catheter in curved lesions. This innovation has been patented and is illustrated in Fig. 2. In vitro experiments have demonstrated that it excels in torque transmission and flexibility compared to previous catheters. Additionally, this catheter boasts a larger inner diameter,

Table 3
Device satisfaction.

	Total	Control	New torque-controlled catheter	New torque-controlled catheter–control catheter	*P* value
				Mean difference (95 % CI)	
Device rotational force satisfaction					<0.001***
1	0	0	0		
2	0	0	0		
3	154 (42.08)	147 (93.63)	7 (3.35)		
4	17 (4.64)	10 (6.37)	7 (3.35)		
5	195 (53.28)	–	195 (93.30)		
Device rotational force satisfaction, (mean ± standard deviation)	4.112 ± 0.971	3.064 ± 0.245	4.900 ± 0.398	1.836 (1.765–1.907)	<0.001***
Operator satisfaction					<0.001***
1	15 (3.60)	15 (7.21)	0		
2	13 (3.12)	13 (6.25)	0		
3	168 (40.29)	167 (80.29)	1 (0.48)		
4	22 (5.28)	13 (6.25)	9 (4.31)		
5	199 (47.72)	–	199 (95.22)		
Operator satisfaction, (mean ± standard deviation)	3.904 ± 1.150	2.856 ± 0.628	4.947 ± 0.244	2.092 (2.000–2.183)	<0.001***
Manufacturer satisfaction					<0.001***
1	15 (3.60)	15 (7.21)	0		
2	9 (2.16)	9 (4.33)	0		
3	172 (41.25)	171 (82.21)	1 (0.48)		
4	22 (5.28)	13 (6.25)	9 (4.31)		
5	199 (47.72)	–	199 (95.22)		
Manufacturer satisfaction, (mean ± standard deviation)	3.914 ± 1.138	2.875 ± 0.617	4.947 ± 0.244	2.072 (1.982–2.163)	<0.001***

Very dissatisfied = grade 1; Dissatisfied = grade 2; Ordinary = grade 3; Satisfied = grade 4; Very satisfied = grade 5.
Data presented as mean ± standard deviation or number.
Continuous variables were compared using Student's *t*-test.
*$P < 0.05$; **$P < 0.01$; ***$P < 0.001$.

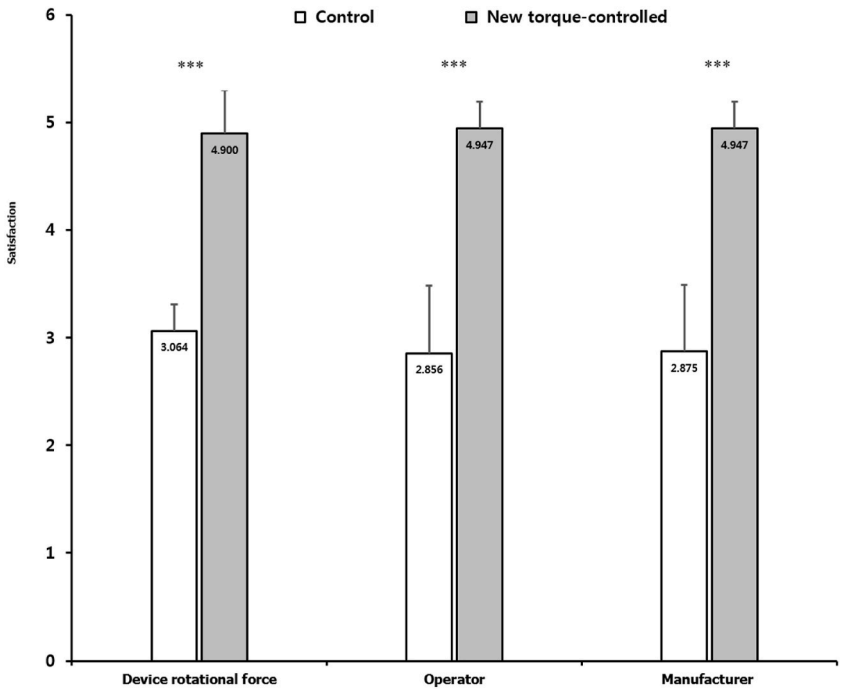

Fig. 4. Device satisfaction score (mean ± SD) of new torque-controlled catheter compared with control group catheter * P < 0.05; **P < 0.01; ***P < 0.001.

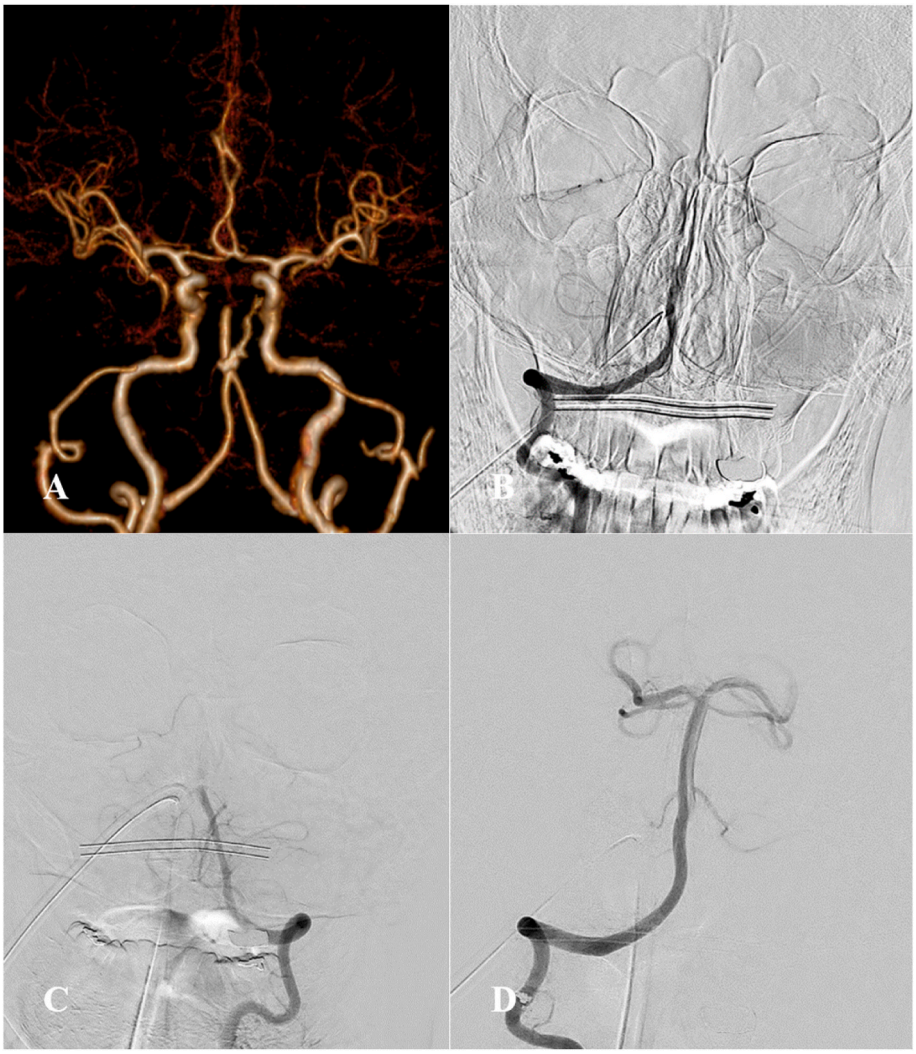

Fig. 5. (A) Brain 3-dimensional computed tomographic angiography (B) Right vertebral artery angiography (C) Left vertebral artery angiograph (D) Final angiography of right vertebral artery after recanalization.

leading to superior flow performance. Specifically, the new torque-controlled catheter showed a flow rate of 28.31 mL/min compared to 22.18 mL/min for the Cook catheter, confirming its larger inner diameter in actual flow performance tests.

As observed in a previous study [17], when the flexibility of the catheter was improved, the torque transmission power for the catheter decreased. The new torque-controlled catheter showed better results in terms of technical success rate, aortic arch access, and common carotid artery access.

In aortic arch type 2,3 control group technical success rate was 83.52 % (76 out of 91) and new torch controlled catheter group success rate was 96.63 % (86 out of 89). When crossover with the new torque-controlled catheter was performed, 13 out of 15 were successful (86.67 %) after failure in the control group. In aortic arch types 2 and 3, the catheters in the control group did not receive sufficient trackability force and did not perform common carotid artery selection. However, the new torque-controlled catheter succeeded in common carotid artery selection with better torsion stability in a crossover situation and showed higher technical success rate. The torque transmission power of the catheter is important in cerebral angiography. Without proper torque transmission power, entering aortic arch type 2 or 3 or the vertebral artery orifice becomes challenging, and internal carotid artery or external carotid artery selection becomes difficult in common carotid artery validation. If the rotation force of the 1:1 ability is poor, complications such as cerebrovascular damage caused by catheters, delamination, and thrombus occurrence increase. The rotation force of the device on the new torque-controlled catheter increased over that of the control group catheters by overcoming the torque transmission power through a combination of optimized polymer materials and braid-wire structures.

In a previous studies [16–18], the incidence of cerebral angiography complications was 1–12 %, and that of transfemoral cerebral angiography was 1–9%. The neurological complication rate of transfemoral cerebral angiography was 1–3%, and the percentage of persistent morbidity was 0–1%. The current study was conducted by experienced experts who perform more than 300 cerebrovascular

procedures each year at four university hospitals in Korea. No complications occurred, and the efficacy of the instrument could be evaluated more accurately. Furthermore, it was possible to distinguish the superiority of the rotational and entry forces.

A typical 5 Fr catheter has an inner diameter of 1.05 mm and an outer diameter of 1.65 mm. In contrast, the new torque-controlled catheter is a 5F catheter with an inner diameter of 1.20 mm and an outer diameter of 1.70 mm. This catheter is thin but has a hard wall, making it possible to be used as a guiding catheter. It has many advantages in neurointervention, needing to be changed several times, from diagnostic angiography to neurointervention. First, the catheter could be used to insert one microcatheter and perform advanced procedures, such as aneurysm coiling or mechanical thrombectomy, while connecting the irrigation system immediately after cerebral angiography. In an emergency, thrombectomy can be performed, as in this case (Fig. 5), to short the procedure time and reduced medical expenses. In coil embolization, the new torque-controlled catheter can be used as a guiding catheter in thin blood vessels with an average inner diameter of 2.46–4 mm, such as the vertebral arteries [19]. Second, it is possible to obtain a good angiographic image by increasing the amount of contrast injection with a wide inner diameter. As shown in Fig. 3b, a successful contrast image can be obtained by connecting the guidewire to the continuous irrigation system (Fig. 1) and employing a 4 cc/sec contrast agent. Third, the new torque-controlled catheter is more clearly visible on fluoroscopy compared to other catheters (Fig. 3c and d). The catheter is more clearly distinguished in the aortic arch, which reduces fluoroscopy time and enables angiography with reduced radiation doses. Cerebrovascular angiography can be performed more easily in situations in which the patient is moving continuously or is breathless.

The majority of the control group catheters used were Cook catheters, with some Terumo catheters included. This selection reflects market trends, mirroring the distribution of diagnostic angiographic catheters in the market. This comparative study focused on the newly developed catheter, with Cook catheters representing most of the market, which facilitated the analysis.

Since its development, the new catheter is increasingly being adopted in major hospitals and cardiovascular centers, particularly for elderly patients. It is gradually becoming a valuable tool for transfemoral cerebral angiography in clinical practice.

This study has a some limitations. The complication rate was 0 % in both groups because it was performed by three expert neurointerventionalists. Therefore, several large-scale, well-designed studies are required to verify this factor.

5. Conclusion

The new torque-controlled catheter presented herein is an effective and safe diagnostic catheter for cerebral angiography. It has considerable flexibility and better control of the rotation force by 1:1, as well as better visibility during fluoroscopy. The increased inner diameter of the new torque-controlled catheter resulted in high-quality images with a larger contrast flow. If immediate neurointervention after cerebral angiography is required in some cases, the time required for angiography can be reduced by using the new torque-controlled catheter.

IRB institutions and the approval protocol number

The institutional review boards of all the participating hospitals, that is, Soonchunhyang University Cheonan Hospital (Cheonan, South Korea), Soonchunhyang University Seoul Hospital (Seoul, South Korea), Dankook University Hospital (Cheonan, South Korea), and Inje University Ilsan Paik Hospital (Goyang, South Korea), approved this study (SCHCA 2020-06-031).

Trial registration number

This trial has been registered at cris.nih.go.kr (KCT0005718).

Funding

This research was supported by The Catholic University of Korea Uijeongbu St. Mary's Hospital Clinical Research Laboratory Foundation and the Korea Medical Device Development Fund grant funded by the Korean government [Ministry of Science and ICT, Ministry of Trade, Industry and Energy, Ministry of Health & Welfare, Republic of Korea (202015X17)] and Bio & Medical Technology Development Program of the National Research Foundation (2023R1A2C100531).

Data availability statement

All data generated or analyzed during this study are included in this published article. The datasets used and/or analyzed during the current study available from the corresponding author on reasonable request.

CRediT authorship contribution statement

Seung Min Shin: Writing – original draft, Visualization. **Ji Young Lee:** Software. **Heo Nam Hun:** Data curation. **Se Woong Choo:** Funding acquisition. **Yong Pyo Jeon:** Funding acquisition. **Jaewoo Chung:** Resources. **Jung Ho Ko:** Validation. **Hae-Won Koo:** Writing – review & editing. **Dong Seoung Shin:** Supervision. **Man Ryul Lee:** Investigation, Formal analysis. **Jae Sang Oh:** Project administration, Funding acquisition, Conceptualization.

Declaration of competing interest

The authors declare that they have no known competing financial interests or personal relationships that could have appeared to influence the work reported in this paper.

Appendix A. Supplementary data

Supplementary data to this article can be found online at https://doi.org/10.1016/j.heliyon.2024.e35205.

References

[1] W. Ziliang, J. Xia, W. Wang, G. Xu, J. Gu, Y. Wang, et al., Transradial versus transfemoral approach for cerebral angiography: a prospective comparison, J. Interv. Med. 2 (2019) 31–34, https://doi.org/10.1016/j.jimed.2019.05.008.
[2] S.M. Wolpert, L.R. Caplan, Current role of cerebral angiography in the diagnosis of cerebrovascular disease, Am. J. Roentgenol. 159 (1992) 191–197, https://doi.org/10.2214/ajr.159.1.1609697.
[3] R.A. Willinsky, S.M. Taylor, K. TerBrugge, R.I. Farb, G. Tomlinson, W. Montanera, Neurologic complications of cerebral angiography: prospective analysis of 2,899 procedures and review of the literature, Radiology 227 (2003) 522–528, https://doi.org/10.1148/radiol.2272012071.
[4] V. Alakbarzade, A.C. Pereira, Cerebral catheter angiography and its complications, Prac. Neurol. 18 (2018) 393–398, https://doi.org/10.1136/practneurol-2018-001986.
[5] T.F. Johanna, P.M. Meyers, S.D. Lavine, V. Cox, L. Silverberg, S. Mangla, et al., Complications of modern diagnostic cerebral angiography in an academic medical center, J. Vasc. Interv. Radiol. 20 (2009) 442–447, https://doi.org/10.1016/j.jvir.2009.01.012.
[6] Y. Matsumoto, K. Hongo, T. Toriyama, H. Nagashima, S. Kobayashi, Transradial approach for diagnostic selective cerebral angiography: results of a consecutive series of 166 cases, Am. J. Neuroradiol. 22 (2001) 704–708.
[7] Y. Wonki, W.K. Kwon, O. Choudhri, J. Ahn, H. Huh, C. Ji, et al., Complications following transradial cerebral angiography: an ultrasound follow-up study, J. Korea Neurosurg. Soc. 61 (2018) 51–59, https://doi.org/10.3340/jkns.2017.0209.
[8] T.J. Kaufmann, J. Huston, J.N. Mandrekar, C.D. Schleck, K.R. Thielen, D.F. Kallmes, Complications of diagnostic cerebral angiography: evaluation of 19,826 consecutive patients, Radiology 243 (2007) 812–819, https://doi.org/10.1148/radiol.2433060536.
[9] B. Kwon, K.B. Lee, J.T. Yoon, J.H. Choi, D.H. Lee, Y. Song, Safety and effectiveness of the novel catheter 3.0 system for diagnostic cerebral angiography: a pilot study, Neurointervention 17 (2022) 143–151, https://doi.org/10.5469/neuroint.2022.00248.
[10] R.J. Rosen, A new catheter for selective and superselective angiography, Cardiovasc. Interv. Radiol. 9 (1986) 49–51, https://doi.org/10.1007/BF02576986.
[11] R.L. Mani, A new double-curve catheter for selective femorocerebral angiography, Radiology 94 (1970) 607–611, https://doi.org/10.1148/94.3.607.
[12] I. Obrez, A "wire-whip" catheter for selective catheterization of aortic branches, Cardiovasc. Radiol. 1 (1978) 193–197, https://doi.org/10.1007/BF02552032.
[13] W.C. Blackwelder, Proving the null hypothesis, clinical trials, Control. Clinic. Trials 3 (1982) 345–353, https://doi.org/10.1016/0197-2456(82)90024-1.
[14] A.C. Tamhane, B.R. Logan, A superiority-equivalence approach to one-sided tests on multiple endpoints in clinical trials, Biometrika 91 (2004) 715–727, https://doi.org/10.1093/biomet/91.3.715.
[15] D. Grieb, M. Schlunz-Hendann, W. Brinjikji, K. Melber, B. Greling, H. Lanfermann, et al., Mechanical thrombectomy of M2 occlusions with distal access catheters using ADAPT, J. Neuroradiol. 46 (2019) 231–237, https://doi.org/10.1016/j.neurad.2019.01.096.
[16] T.J. Kaufmann, J. Huston, J.N. Mandrekar, C.D. Schleck, K.R. Thielen, D.F. Kallmes, Complications of diagnostic cerebral angiography, Radiology 243 (2007) 812–819, https://doi.org/10.1148/radiol.2433060536.
[17] A.A. Dawkins, A.L. Evans, J. Wattam, C.A. Romanowski, D.J. Connolly, T.J. Hodgson, et al., Complications of cerebral angiography: a prospective analysis of 2,924 consecutive procedures, Neuroradiology 49 (2007) 753–759, https://doi.org/10.1007/s00234-007-0252-y.
[18] M. Alonso, J. Tascón, F. Hernández, J. Andreu, A. Albarrán, M.T. Velázquez, [Complications with femoral access in cardiac cathetization. Impact of previous systematic femoral angiography and hemostasis with VasoSeal-ES collagen plug], Rev. Esp. Cardiol. 56 (2003) 569–577, https://doi.org/10.1016/s0300-8932(03)76918-8.
[19] A.D. Tarnoki, B. Fejer, D.L. Tarnoki, L. Littvay, P. Lucatelli, C. Cirelli, et al., Vertebral artery diameter and flow: nature or nurture, J. Neuroimag. 27 (2017) 499–504, https://doi.org/10.1111/jon.12434.